

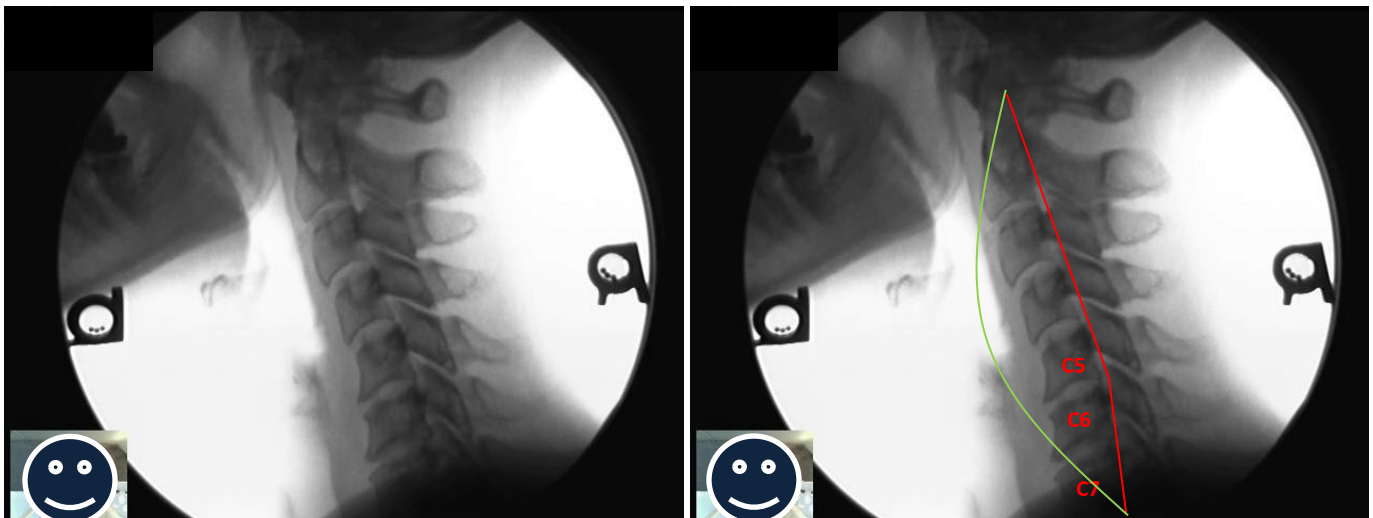
NAME OF PATIENT: Your Patient
DATE OF REPORT: 6/12/2023
DATE OF EXAMINATION: 6/8/2023
REFERRING PHYSICIAN: Your Name Here
TESTING FACILITY: Arizona Digital Motion X-ray



Digital Motion X-ray Cervical Spine

1. In the neutral lateral projection: Shows reversal of the cervical lordosis, with the apex of the reversal at the level of C5-C6. There is disc narrowing and spurring at C5-C6 and C6-C7.

The integrity of the cervical lordosis and overall condition of the cervical spine is evaluated. The loss of the cervical lordosis may be a result of damage to the posterior longitudinal, capsular or interspinous ligaments.



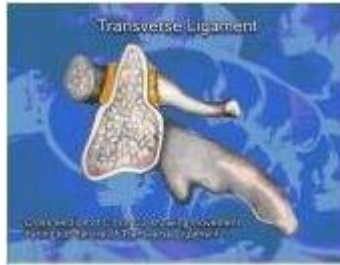Neutral lateral projection

NAME OF PATIENT:
DATE OF REPORT:
DATE OF EXAMINATION:

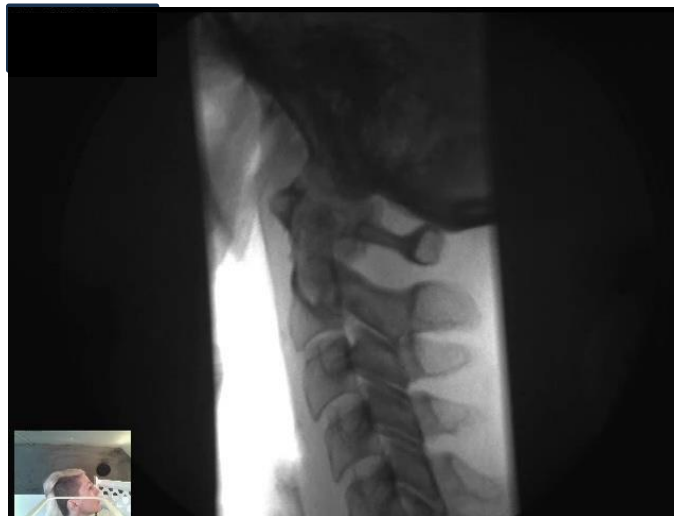Your Patient
6/12/2023
6/8/2023

2. In the lateral nodding projection movement at the atlanto-occipital articulation: Is within normal limits.

This view examines the integrity of the transverse ligament which is responsible for preventing the anterior movement of C1 on C2. An increase of the Atlanto-Dens interspace (ADI) indicates damage to the transverse ligament.



Increased ADI space



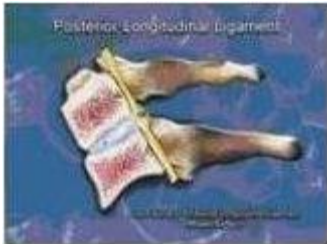Lateral nodding projection

NAME OF PATIENT:
DATE OF REPORT:
DATE OF EXAMINATION:

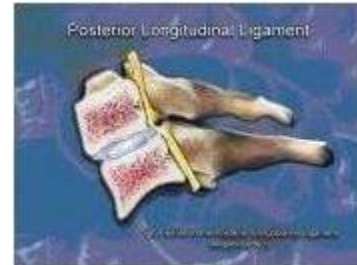
Your Patient
6/12/2023
6/8/2023

3. Motion in the neutral lateral projection to full flexion: There is an anterolisthesis of C3 on C4 and C4 on C5. There is increased separation between the spinous processes at C3-C4, C4-C5, and C5-C6.

This view examines the integrity of the posterior longitudinal ligament demonstrated by a forward (anterior) movement of one vertebrae over the vertebrae below or by the posterior widening of the intervertebral disc space (increased disc angle).




Widening of posterior disc space

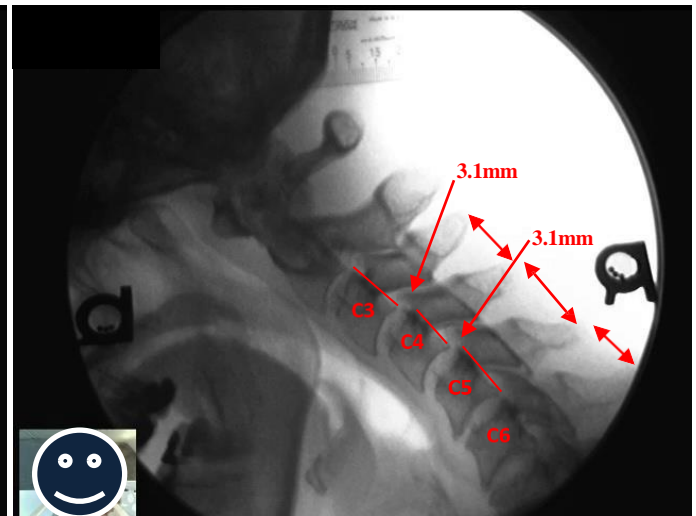
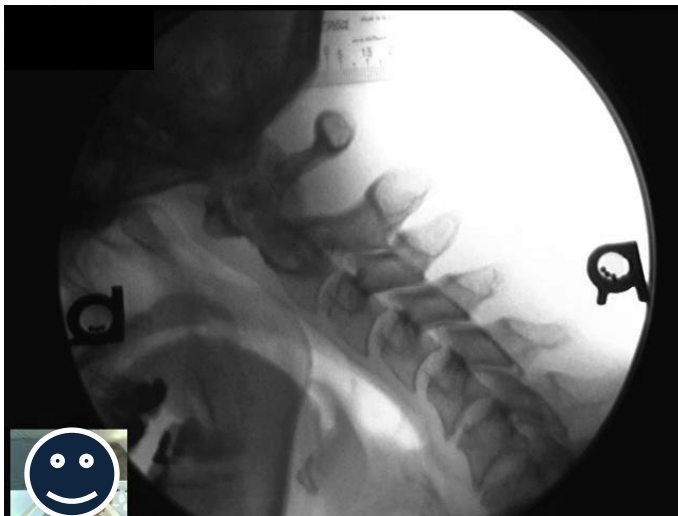

Anterolisthesis

The integrity of the interspinous ligament is evaluated in the lateral flexion view. Damage to this ligament results in increased separation of the spinous processes in flexion.



Damaged Interspinous Ligament



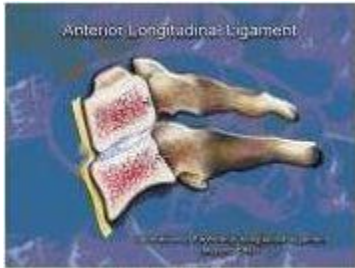
Full flexion projection

NAME OF PATIENT:
DATE OF REPORT:
DATE OF EXAMINATION:

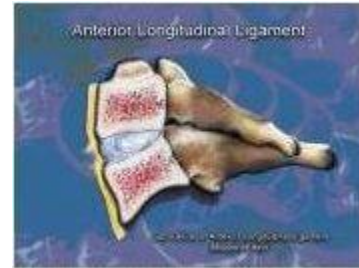
Your Patient
6/12/2023
6/8/2023

4. Motion in the neutral lateral projection to full extension: There is a retrolisthesis of C3 on C4, C4 on C5, and C5 on C6.

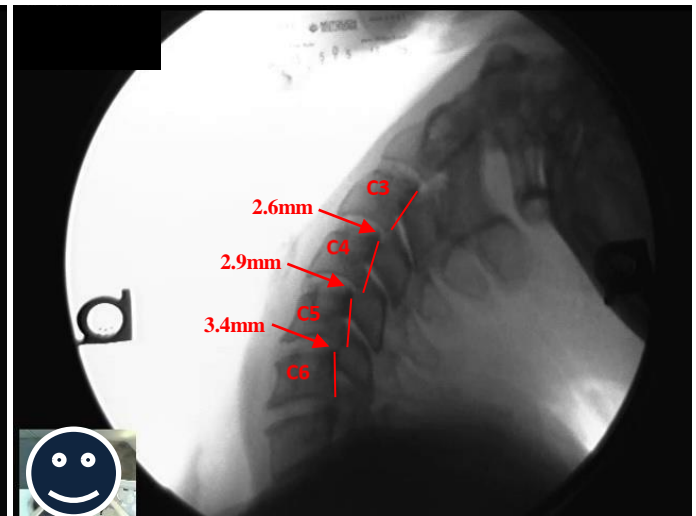
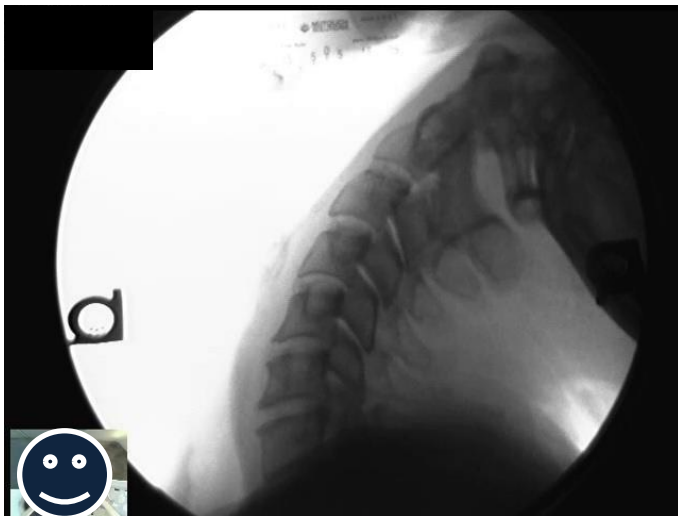This view examines the integrity of the anterior longitudinal ligament demonstrated by a backward (posterior) movement of one vertebrae over the vertebrae below or by the anterior widening of the intervertebral disc space (increased disc angle).



Retrolisthesis



Widening of the anterior disc




Full Extension

NAME OF PATIENT:
DATE OF REPORT:
DATE OF EXAMINATION:

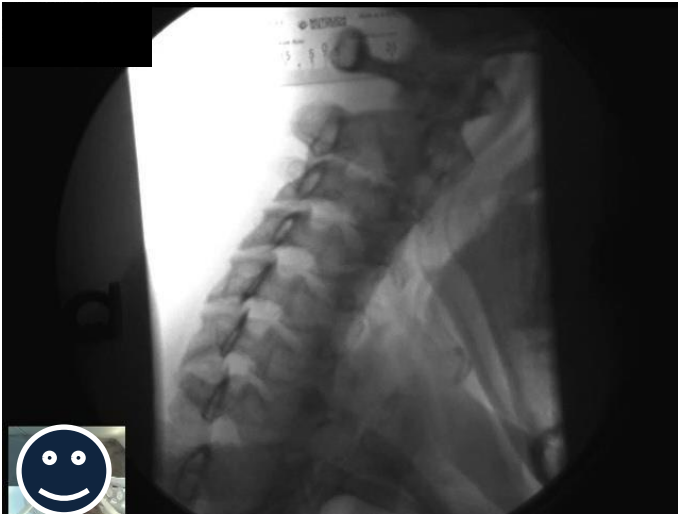Your Patient
6/12/2023
6/8/2023

5. Motion in the oblique flexion projection: There is gapping of the facet joints at C5-C6 bilaterally, C6-C7 bilaterally, and C7-T1 bilaterally.

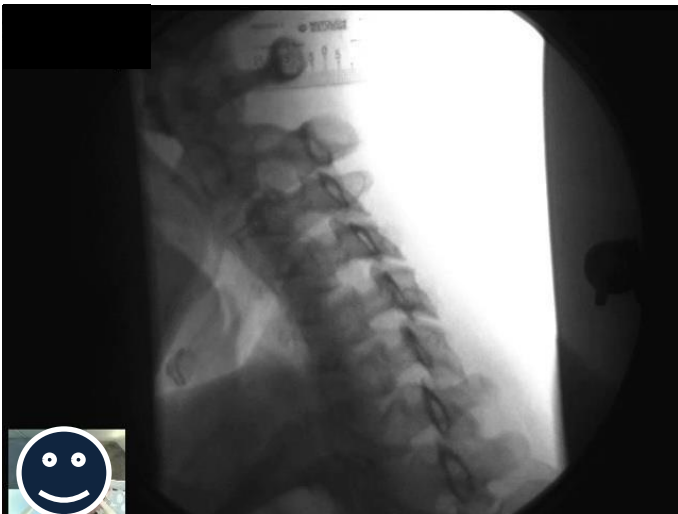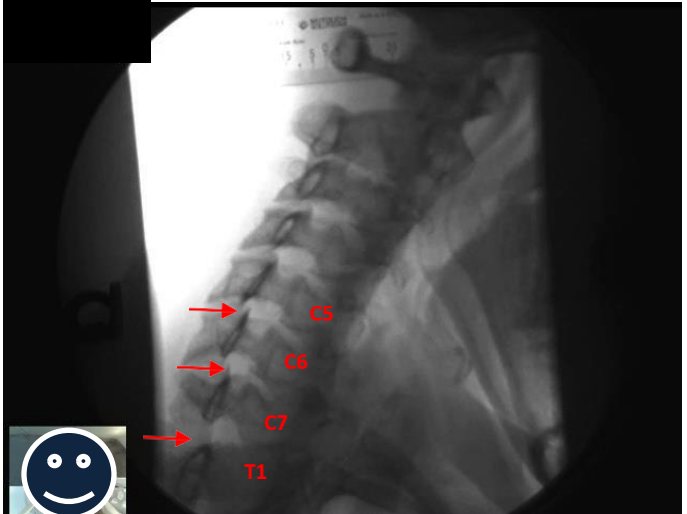This view examines the integrity of the capsular ligaments by observing gapping of the facet joints, located on the posterior cervical spine (C2-C7), there are five capsular ligaments on the right and the left.



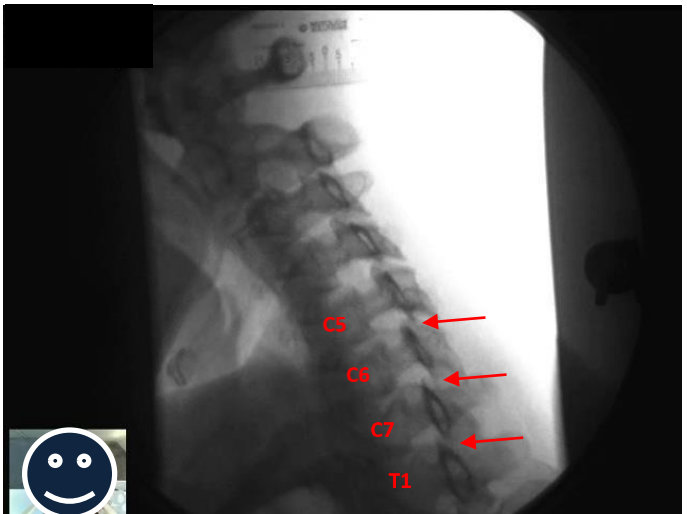
Capsular ligament damage



Left IVF flexion



Right IVF flexion

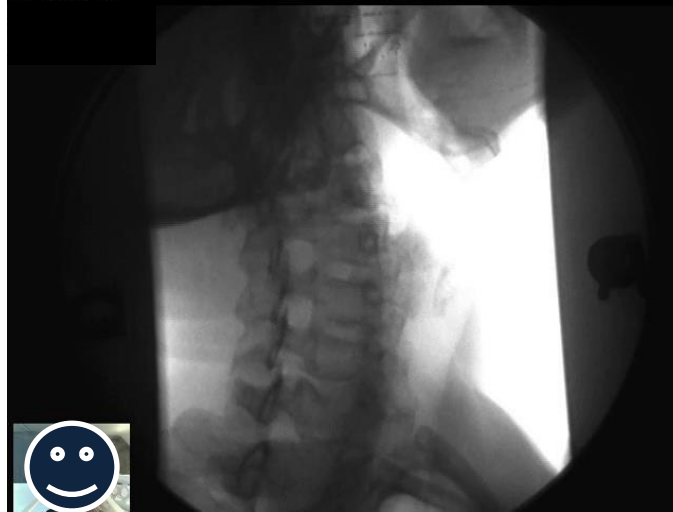

NAME OF PATIENT:
DATE OF REPORT:
DATE OF EXAMINATION:

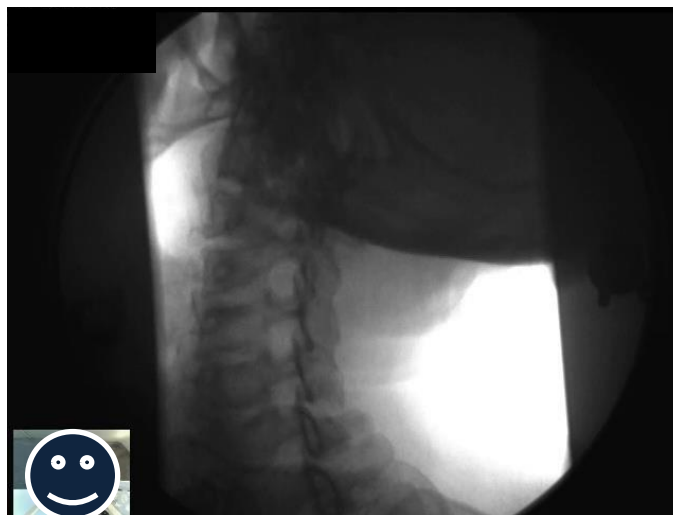Your Patient
6/12/2023
6/8/2023

6. Motion in the oblique extension projection: Is restricted.

This view examines the integrity of the capsular ligament by encroachment into the intervertebral foramen, located on the posterior cervical spine (C2-C7), there are five capsular ligaments on the right and the left.



Left IVF oblique extension



Right IVF oblique extension

7. Motion in the A-P projection lateral bending: Is restricted on the right.

This view allows us to evaluate coupled motion of the spinous processes which examines facet joint integrity.

8. Motion in the A-P rotation projection: Is within normal limits.


This view examines the rotational range of motion between Occiput-C1-C2. Increased motion indicates damage to the alar and accessory ligaments.

NAME OF PATIENT:
DATE OF REPORT:
DATE OF EXAMINATION:

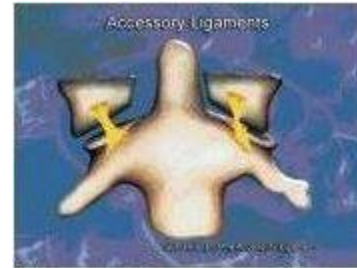
Your Patient
6/12/2023
6/8/2023

9. Motion in the A-P open mouth lateral bending projection: There is a significant abnormal lateral translation of C1 on C2 with an overhang bilaterally.

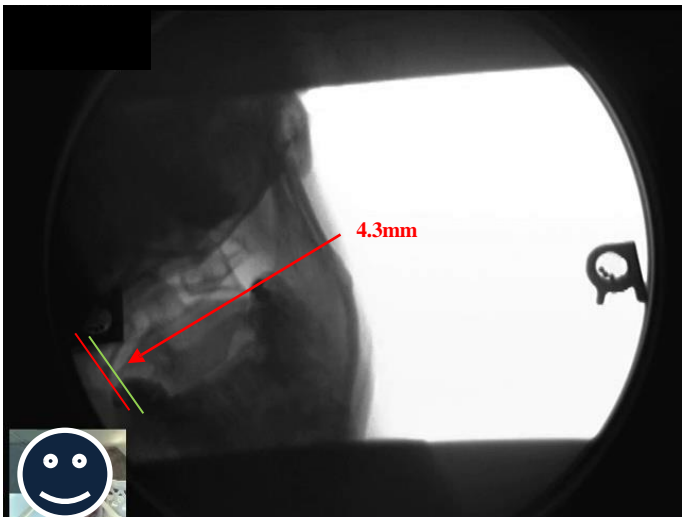
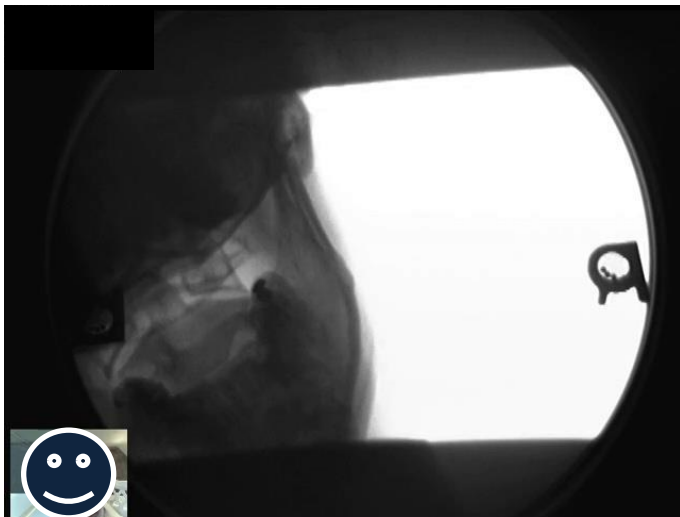This view examines the integrity of the alar and accessory ligaments either by the lateral overhang of C1 on C2 or by the changes in the para-odontoid spaces.



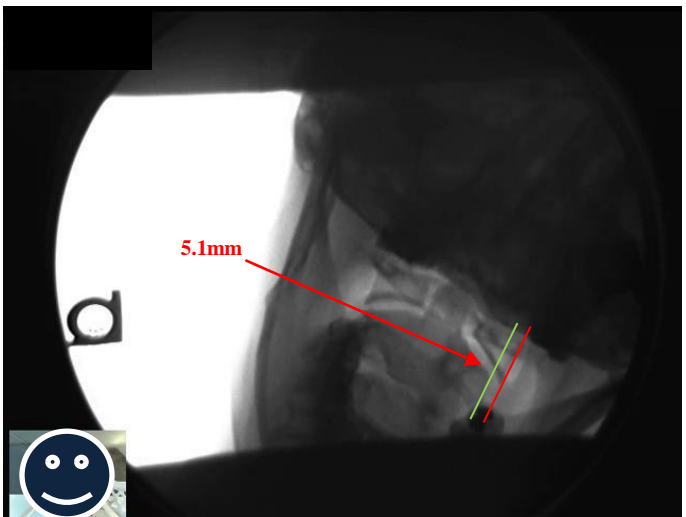
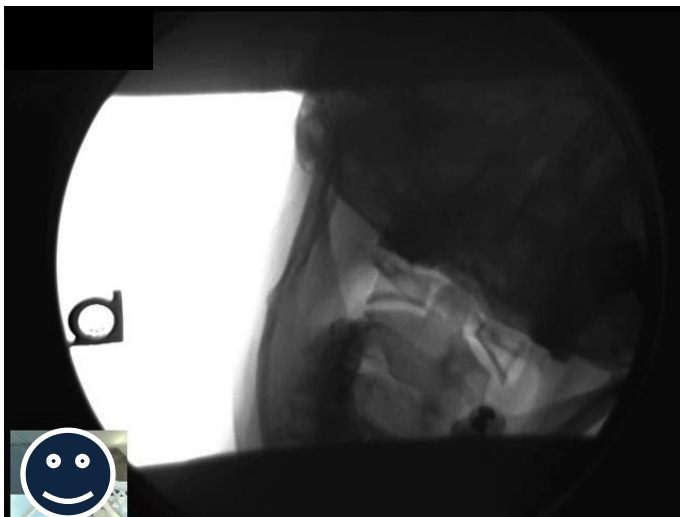C1 lateral mass overhang



Change in Para-odontoid space



Open mouth left lateral bending



Open mouth right lateral bending

NAME OF PATIENT:
DATE OF REPORT:
DATE OF EXAMINATION:

Your Patient
6/12/2023
6/8/2023

IMPRESSION for patient (Your Patient):

- Damage to the posterior longitudinal ligament is indicated by an anterolisthesis at C3 on C4 and C4 on C5. Damage to the interspinous ligament is indicated by a separation between C3-C4, C4-C5, and C5-C6 spinous processes.
- Damage to the anterior longitudinal ligament is indicated by a retrolisthesis at C3 on C4, C4 on C5, and C5 on C6.
- Damage to the capsular ligament is indicated by gapping of the facet joint at C5-C6 bilaterally, C6-C7 bilaterally, and C7-T1 bilaterally.
- Damage to the alar and accessory ligaments is indicated by a significant overhang of the lateral mass of C1 bilaterally.

Note: The term “Damage” as used in this report concerning any ligament represents a ligamentous laxity or instability due to excess stretching or tearing, and is therefore painful, progressive, and permanent.



John R. Postlethwaite, D.C.
Signature electronically applied
JP/lp